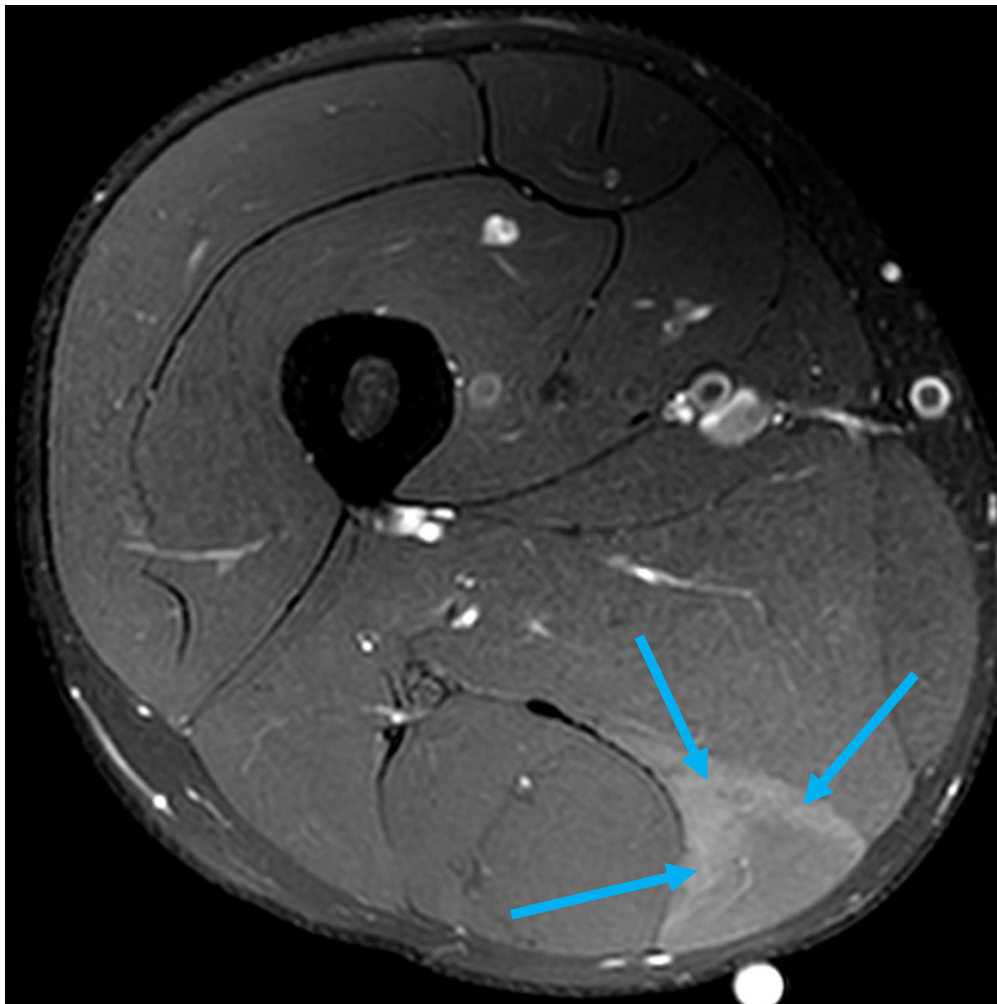


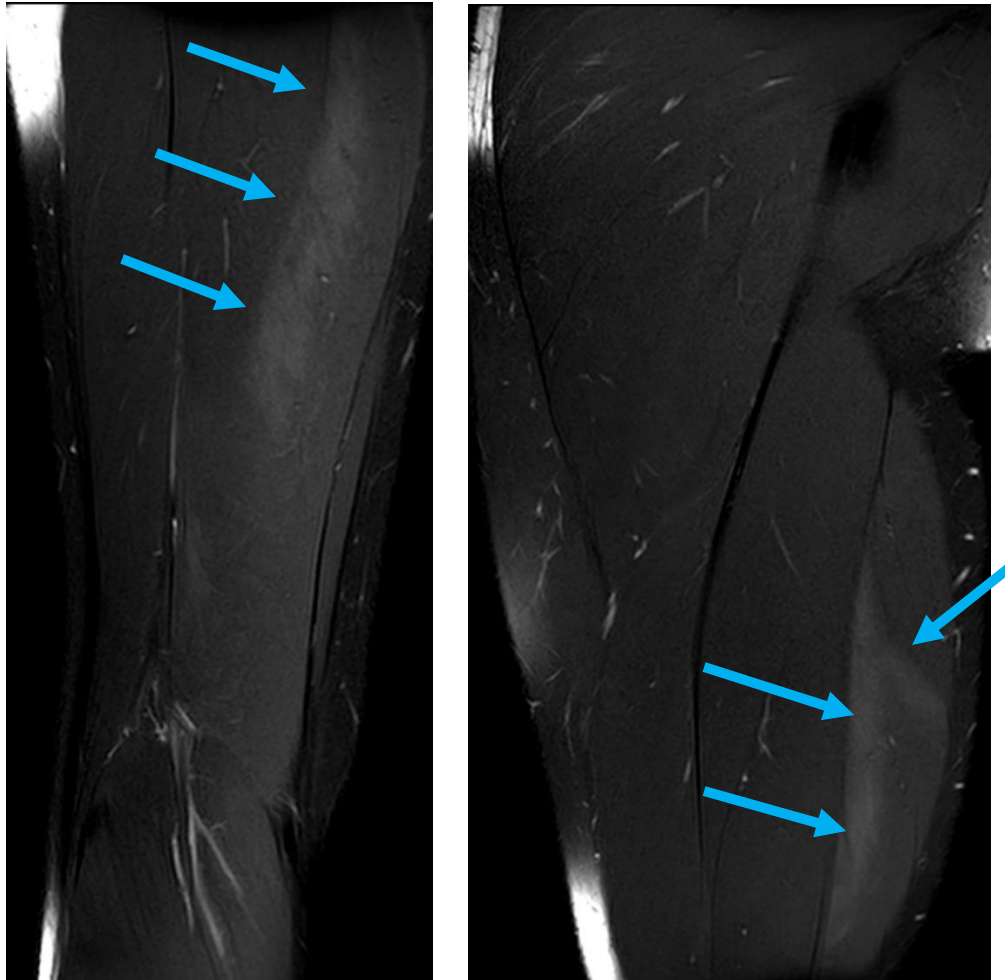
20 M footballer presents with acute medial right hamstring tightness for investigation. Strain?

MRI Findings:

- Surface marker in the region of clinical concern corresponds to semimembranosus muscle - middle third right thigh
- Swirly, cloud-like hyperintensity hugging the epimysial boundaries compatible with DOMS/muscle oedema/overload
- No muscle tear or bleeding evident
- Epimysial boundaries and intra-muscular tendon are preserved
- Semitendinosus and biceps femoris are preserved and the sciatic nerve appears normal



Axial PD SPAIR: Swirled cloud-like hyperintensity hugging the epimysial boundaries at skin marker level



Cor PD SPAIR: Images again nicely demonstrate the cloud-like high signal hugging intact epimysial boundaries

Discussion

- Delayed Onset Muscle Soreness (DOMS)
- Oedema a manifestation of exercise-induced microtrauma to muscle producing the clinical syndrome of DOMS
- Eccentric activities induce micro-injury at a greater frequency and severity than other types of muscle actions
- Often peaks ~48-72 hours post exercise
- Excellent prognosis in terms of return to play / training / competition
- MRI imaging test of choice
 - Delineates complex soft tissue anatomy and structures involved
 - Allows accurate assessment for DDx:
 - muscle contusion / haematoma
 - muscle / connective tissue injury (namely intra-muscular tendon and epimysial)
- Ultrasound
 - Limited sensitivity in detecting oedema associated with DOMS
 - Operator dependent
 - Useful for excluding DDx (as above)

Further Reading:

Marqueste T et al. Comparative MRI analysis of T2 changes associated with single and repeated bouts of downhill running leading to eccentric-induced muscle damage. *J Appl Physiol.* 2008; 105(1):299-307.

Theodorou, T et al. Skeletal muscle disease: patterns of MRI appearances. *Br J Radiol.* 2012;85 (1020): e1298-308.

Evans, G et al. Submaximal delayed-onset muscle soreness: correlations between MR imaging findings and clinical measures. *Radiology.* 1998;208 (3): 815-20.

Longo, V et al. Ultrasound Findings of Delayed-Onset Muscle Soreness. *J Ultrasound Med.* 2016 Nov;35(11):2517-2521.

Draghi F et al. Muscle injuries: ultrasound evaluation in the acute phase. *J Ultrasound.* 2013; 16(4):209-14.